

Case Study

Preventing hernia recurrence: optimising mesh use in incisional hernia repair

Lily Goldblatt¹ and Julia Merchant²

¹Medical Sciences Division, University of Oxford, UK

²Nuffield Department of Surgical Sciences, University of Oxford, UK

Keywords:

Incisional hernia, mesh repair, hernia.

Key Learning Points

Julia Merchant

Incisional hernia is a common complication of abdominal surgery, affecting up to a quarter of patients undergoing laparotomy. This case report discusses a 72-year-old lady with a recurrent incisional hernia following an emergency Hartman's procedure. The discussion covers the properties of synthetic vs biological meshes, the significance of the anatomical location of the mesh, fixation methods, laparoscopic surgery, short and long term complications.

Key points:

- The ideal mesh is biocompatible, strong, resistant to infection, has minimal bioreactivity and non-immunogenic
- Pore size is important to the degree of mesh integration, infection risk and the development of chronic pain
- Synthetic mesh is useful in contaminated cases but adds a significant cost to the procedure
- Sublay mesh placement is associated with a reduced risk of recurrence
- Most recurrences occur at the edge of the mesh. Surgeons should ensure a 5cm overlap between the mesh and native tissues and consider dual fixation methods
- Laparoscopic hernia repair has been associated with a shorter post-op recovery, less pain and a short term reduced risk of recurrence, however there is a greater risk of bowel injury and development of adhesions
- Composite meshes can reduce the risk of adhesions with intraperitoneal mesh placement
- Chronic pain is associated with the use of tacks, heavy weight synthetic meshes and chronic infection
- Resorbable meshes have not been shown to reduce chronic pain
- The choice of mesh, method of repair and surgical approach should be individualised to the patient.

Introduction

Incisional hernias are ventral hernias that form through an operation scar and are an important complication of abdominal surgery, occurring in 11-23% of laparotomies¹. Hernias can be associated with pain at the site of the hernia and limitations of activity and have the potential to incarcerate or strangulate, causing serious morbidity. Surgical repair of hernias involves closing the defect in the abdominal wall through which the hernia forms and is one of the most commonly performed operations globally. Complications associated with repair include hernia recurrence, infection, pain and adhesions. With an estimated yearly rate of 10,000 incisional hernia repairs being carried out in the UK and 100,000 in the USA², it is important that the technique used carries the lowest probability of recurrence and other complications.

Hernia repair has made use of meshes since the middle of the 20th century. Meshes form a scar-mesh complex that seals off the defect in the wall, producing a

mechanical seal that is infiltrated by surrounding tissue. Mesh implantation has replaced suturing as the favoured mode of repair as it reduces the rate of hernia recurrence: 10-year incisional hernia recurrence rates for suture repair are 63% without mesh and 32% for repairs using mesh³.

However, risk of recurrence varies with different mesh types, mesh position and methods of fixation. Materials used range from synthetic to biologic, absorbable to non-absorbable, and the placement and securement of these meshes vary. All methods intend to repair and reinforce the break in the abdominal wall, restoring wall strength without impairing elasticity. Greater understanding of the processes underlying mesh incorporation into tissue have led to the development of more complex meshes, designed to reduce complications. With the expansion of materials available, ranging from synthetic polymers to acellular matrices in biological meshes, there remains clarification to be made as to which meshes result in the best outcomes, with fewer complications and lower rates of recurrence, and

how mesh use can be optimised to further reduce the risk of recurrence. Further understanding of the outcomes of different mesh types and the characteristics of successful mesh design and insertion will help to ensure the best use of mesh in hernia repair.

Case history

Mrs S is a 72-year-old lady who underwent emergency laparotomy in November 2014 and had a Hartmann's procedure for perforated sigmoid diverticular disease. Following this operation, she was in hospital for 15 weeks, including a long stay in intensive care. As a result of this surgery she was left with a large abdominal wall defect, with wide separation of the recti and thin skin overlying. In 2016 she underwent reversal of the colostomy with incisional hernia repair using sutures but subsequently developed a large midline hernia in the lower abdomen with an approximately 8 cm defect. In May 2019 she underwent hernia repair with abdominal wall reconstruction to close the defect with use of a 30x30cm Cellis biological mesh fixed with maxon absorbable sutures.

She has a history of arthritis, unilateral deafness, Type 2 Diabetes mellitus, hypertension and back pain for which she has undergone spinal surgery.

She takes bisoprolol 5 mg, Laxido 1 sachet, metoclopramide 30 mg, omeprazole 20 mg, paracetamol 4000 mg, lisinopril 10 mg, amlodipine 5 mg, atorvastatin 20 mg, tramadol 200 mg, Desunin 800 IU, ferrous sulfate 600 mg, meloxicam 25 mg. She is allergic to ibuprofen and has hay-fever.

She lives alone in a private owned bungalow with a single step and a rail in place. Her daughter lives nearby and is her main carer following operations. She is a retired post office counter clerk. She stopped smoking 40 years ago, before which she smoked 10 a day for 20 years.

Mesh types

Meshes form structural scaffolds which reinforce the weakened area and provide tension-free repair that facilitates tissue infiltration and fibro-collagenous tissue formation. In this way, they promote the development of healthy tissue to restore structural integrity. Meshes used in hernia repair were revolutionised by the development of plastics in the mid 20th century (figure 1), with synthetic meshes appearing in 1958 with good outcomes.

Synthetic meshes are composed of four main groups of materials: polypropylene (PP), polyester, ePTFE and PTFE. Their design has been influenced by tissue engineering, which aims to design materials that meet the structural and mechanical requirements of the normal tissue being replaced so as to carry out its normal function. The ideal synthetic mesh must be biocompatible, strong, resistant to infection, have minimal bioreactivity and be non-immunogenic.

Insertion of a mesh induces a foreign body response which consists of an initial inflammatory response, followed by intense deposition of fibrotic tissue resulting in permanent encapsulation of the mesh into host tissues. As such, the mesh acts as a scaffold into which fibrotic tissue is incorporated. It was initially thought that the best meshes would be those that induce the largest fibrotic responses. Too large responses however result in pain and movement restriction⁴, major complications that affect quality of life following repair. Meshes must therefore induce a large enough fibrotic response for tissue integration without over activity restricting benefit.

Meshes are formed by weaving or knitting filaments (multifilaments or monofilaments) into sheets which contain pores. Porosity determines the extent of tissue integration by controlling infiltration by different cell types and influences hugely the complications associated with mesh repair. Pore size must be greater than 75µm to allow for fibroblast, blood vessel and collagen infiltration, as well as macrophage infiltration to enable immune cell surveillance.

The weight of the mesh is determined by the weight of the polymer and the amount of material used. Heavyweight meshes use thin polymers, have small pore sizes and higher tensile strength, whereas lightweight meshes have thinner filaments and larger pores, use less material and are more elastic (figure 2). In a study comparing the use of lightweight and heavyweight PP meshes in ventral hernia repair, Schmidbauer et al.⁵ found that 38% of patients given heavyweight PP meshes experienced foreign body sensations in the abdominal wall, as opposed to 4% of those given lightweight PP meshes. Furthermore, lightweight meshes produced decreased foreign body reaction, had better tissue incorporation and decreased patient discomfort and pain. Lightweight meshes thus appear superior, with the differences in outcome attributable to the difference in pore size.

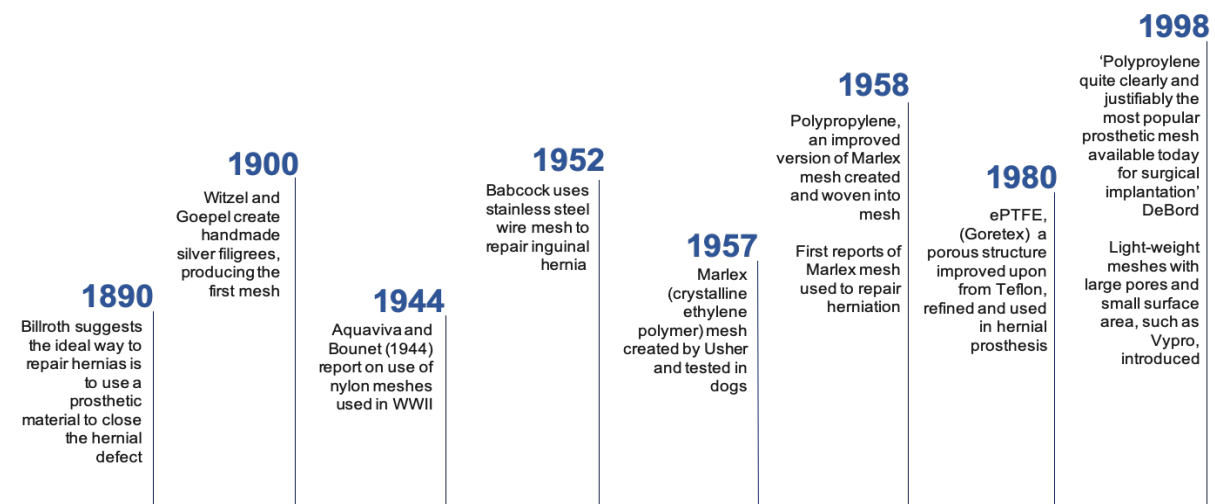


Figure 1: Timeline of mesh development

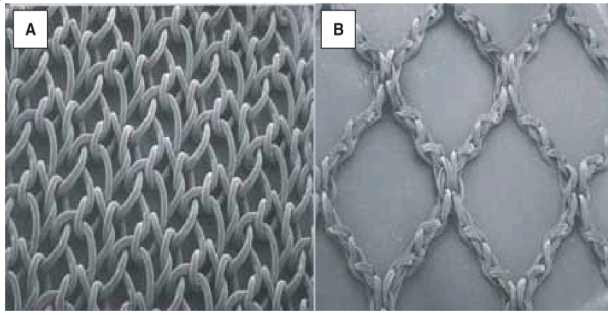


Figure 2: Structure of heavyweight small porous mesh (A) and lightweight, large porous mesh in (B). Kinge et al, 2005¹¹.

Biologic grafts pose an alternative to synthetic meshes, which have good outcomes although carry substantial financial cost. They are composed of acellular collagen matrices obtained from human or non-human sources that is processed for medical use, and like synthetic meshes, provide a scaffold onto which native tissue is incorporated. Biologic meshes differ in their source (human, porcine, bovine), processing (stripping, cross linking) and composition (dermal, pericardial, submucosal).

Biologic meshes are superior to synthetic meshes in their resistance to infection and are more often used in contaminated fields in which synthetic meshes would be inappropriate. The infection resistance together with the level of tissue incorporation achieved with biologic meshes also renders them superior in non-contaminated settings, carrying success rates of better than 90% in clean fields⁶. Tissue incorporation was shown to be extensive in a study investigating onlay repair of porcine dermal biologic mesh. In 22 patients undergoing hernia repair, only one patient had hernia recurrence, and investigation of mesh incorporation at 4 months post-op showed extensive vascularisation and fibroblast infiltration⁷. Reduced short-term recurrence rates and rare occurrence of major complications have also been documented with biologic meshes, with no difference existing between porcine and human biologic meshes⁸.

Mesh placement and fixation

The site of mesh insertion within the layers of the abdominal wall is important, producing different environments and subjecting the mesh to different pressures generated within the abdomen. As such, the position of the mesh within the abdomen determines the properties required of the mesh. The various positions of mesh placement within the wall and the relative pros and cons are illustrated in table 1. Sublay mesh placement has been found to be associated with lower risk of recurrence and surgical site infection than onlay, inlay and underlay⁹. In the case of Mrs S, the sublay technique between the posterior sheath and the rectus abdominus was the surgeon's preferred method of placement, however the poor integrity of the posterior fascial sheath most likely due to previous surgery resulted in the mesh being placed beneath the posterior sheath in a preperitoneal position.

Once inserted into the hernial site, mesh contraction occurs in all synthetic meshes to a degree, requiring that sufficient overlay of the mesh edges is carried out to account for such changes, with the mesh overlapping the hernia gap by at least 4-5 cm¹⁰. Recurrence following mesh implantation occurs at the free edges of the mesh in 99% cases¹¹ highlighting the importance of sufficient overlap. Inflammation also causes a degree of shrinkage of mesh within the foreign body reaction. This differs between different mesh materials and placement, with woven mesh shrinking less and the sublay technique resulting in the least degree of shrinkage in an animal model of hernia repair using a PP mesh¹².

Mesh fixation is carried out with tacks (absorbable or non-absorbable), staples or transfascial sutures, or a combination of the three. The method of fixation varies with the position of the mesh placement and contributes to the stability and strength of the repair. Post-operative pain has also been linked to the method of mesh fixation¹⁵. In the case of Mrs S the mesh was fixed using sutures only, anchoring the corners of the mesh to the abdominal wall then reinforcing the attachment with sutures placed 5 cm apart along the edges. Arguments

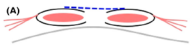

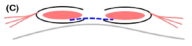
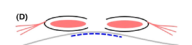
Position	Pros	Cons
Onlay 	<ul style="list-style-type: none"> - Technically easy - Space often already dissected for complex hernias 	<ul style="list-style-type: none"> - Requires skin flaps - Increased risk of wound complications and mesh infection
Inlay 	<ul style="list-style-type: none"> - Technically easy 	<ul style="list-style-type: none"> - Mesh susceptible to superficial wound complications - Lack of overlap increases risk of recurrence - Mesh bridges the gap rather than closing the defect
Sublay 	<ul style="list-style-type: none"> - Space protects mesh from superficial wound complications - Mesh protected from intra-peritoneal contents - Load-bearing tissue ingrowth can occur from two directions 	<ul style="list-style-type: none"> - More complex technically - Risk damaging the rectus abdominus, its blood supply and nerves
Underlay/ intraperitoneal onlay 	<ul style="list-style-type: none"> - Protected from superficial wound complications 	<ul style="list-style-type: none"> - Technically complex - Mesh must be secured with sutures close together to prevent abdominal contents from sliding between mesh and abdominal wall - Mesh exposed to intraperitoneal contents

Table 1: Comparison of mesh placement position. Blue: mesh, red: muscle, black: fascia, grey: hernia sac. Adapted from Holihan et al, 2016⁹.

against the use of suture fixation include the length of fixation time and the difficulty of placement in certain anatomical areas. However suture fixation has been found to have lower recurrence rates than tack fixation (0.8 % vs 1.5 %) in laparoscopic repair¹⁴, with conclusions in this review stating that sutures also reduce the minimum degree of overlap of the mesh with the hernial orifice.

Open vs laparoscopic

Laparoscopic mesh repair involves the insertion of mesh through an incision in the abdominal wall and fixed against the abdominal wall in an intraperitoneal position using tacks or transfascial sutures as with open repair. Laparoscopic repair does not include closure of the hernial orifice but instead relies on the mesh to provide the strength to prevent hernia recurrence. The benefits of laparoscopic repair include shorter hospital stay, fewer wound complications and lesser cost. A Cochrane review found that laparoscopic repair reduced wound infection rate and allowed quicker recovery than open repair, however the technique includes a higher risk of bowel injury¹⁵. Poor long term follow-up of the trials included failed to determine the long-term benefits however Liem et al. found in an earlier randomized control trial that there was a lower rate of recurrence of hernia in patients who had undergone laparoscopic compared to open repair (3% vs. 6% at 2 years follow-up) and shorter recovery time¹⁶. Such results were reproduced in a later retrospective observational study including 68,560 patients which found decreased recurrence and post-operative pain following laparoscopic versus open repair of incisional hernias¹⁷.

Complications following mesh repair

Mesh design, placement and fixation technique all affect the likelihood of complications occurring following hernia repair. The main complication that has been the focus of this report is recurrence.

Visceral adhesions are a common complication of mesh repair and can result in obstruction and future surgical complications. Composite meshes are composed of more than one material, with a visceral side being coated in an absorbable (or non-absorbable) barrier which minimises the biological response and prevents adhesion formation when placed intraperitoneally. Such meshes have been found to reduce adhesions in animal models, however the clinical efficacy is poorly documented as of yet. The intraperitoneal placement of the mesh in the case of Mrs S would have made composite meshes a possible management option.

Another way of reducing the likelihood of adhesion formation is to use meshes that are absorbed completely over time. Such meshes are designed to degrade once the new tissue that develops is capable of maintaining mechanical integrity, reducing the risk of chronic complications. In a study conducted by Ruiz-Jasbon et al.¹⁸, a long-term resorbable implant mesh was found to be an effective management option in inguinal hernia repair. However, a recent systematic review and meta-analysis found no difference in chronic pain or recurrence rate between absorbable and permanent meshes in inguinal hernia repair¹⁹. In contaminated cases where primary abdominal closure is not possible, absorbable meshes may be a possible method of closing a defect until later repair is possible in a non-contaminated setting. Absorbable meshes may thus have potential use in cases that are different to that of Mrs S. Whether a degradable implant would be effective in repairing a defect as large as Mrs S

may require further experimental exploration however the intraperitoneal placement of the mesh in Mrs S' case would have favoured such a mesh.

Chronic pain is an important complication of mesh repair of hernias, occurring in 9% patients²⁰. Small pore meshes are associated with higher rates of chronic pain and as previously stated the mesh fixation technique affects chronic pain. The use of glue in hernia repair instead of sutures has been found to reduce postoperative chronic pain without affecting recurrence rates²¹, posing a potentially superior method of fixation to reduce pain following open repair. Such a method could have been used in the case of Mrs S but was not due to the substantial cost of the glue available for use.

Another important complication of mesh repair is infection. Mesh infections are possible as well as superficial wound infections. The incidence of mesh infection following open repair is greater than following laparoscopic repair (6-10 % vs. 0-5.6 %) ²², with bacterial adherence being required for infection. Lightweight meshes have lower risk of infection than heavyweight meshes, and biologic meshes have much lower risk than synthetic meshes. Pore size is important, with pores <10µm preventing macrophage and neutrophil invasion and thus reducing the host immune response to mesh infection. Antibiotic prophylaxis has been found to give good outcomes in reducing wound infection following hernia repair using mesh²³ however a recent systematic review found the evidence base supporting antibiotic prophylaxis too weak to provide universal recommendations²⁴.

In contaminated cases in which there is exposure to the gastrointestinal tract there is a greater risk of post-operative complications following repairs using mesh. Contaminated cases are 3.56 times more likely to result in post-operative complications than clean cases²⁵. In such cases, biologic meshes have been recommended, with one study showing no significant complications following use of biosynthetic mesh to repair hernias with contaminated wounds in two cases²⁶.

Risk factors for recurrence

There are a number of patient related risk factors for recurrence that have been identified by the International Endohernia Society²⁷ in their guidelines for laparoscopic treatment of ventral and incisional abdominal wall hernias. The main risk factors they identified are listed in table 2. Operating on patients with BMI <30 is preferable and encouraging weight loss can be included as part of preparing the patient for surgery. Smoking cessation should also be encouraged. Mrs S fulfils two of these risk factors, having both diabetes and a history or previous hernia repair. To reduce the likelihood surgical site infection, the guidelines suggest laparoscopic as opposed to open repair. To optimise the effectiveness of the repair they also recommend mesh repair if the defect is larger than 2 cm, overlap of at least 5 cm and dual methods of fixation. The only improvement that could be made according to these guidelines in the

Risk Factors

Size of the hernia >10 cm
Body mass index 30 kg/m ²
History of previous repair
Chronic Obstructive Pulmonary Disease
Diabetes
Smokers with failed prior hernia repair
Surgical site infection

Table 2: Risk factors for hernia recurrence. Adapted from Bittner et al, 2014²⁷.

case of Mrs S is dual method of closure. The location and nature of the defect removed the possibility of operating laparoscopically, however mesh was used and the overlap was over 5 cm from the edge of the abdominal wall defect, fulfilling the other recommendations listed.

Conclusions

Mesh repair has revolutionised hernia repair, reducing recurrence rates remarkably and improving outcomes. The type of mesh used is important, with its design impacting on the major complications such as pore size and infection, however the mode of insertion is equally important and affects the choice of mesh. Knowledge of the features of different meshes and the way in which these affect the incorporation of the mesh into native tissue as well as ways in which to reduce the likelihood of complications should be had by all surgeons carrying out such repairs so as to optimise its use and prevent recurrence. To do this, mesh made of a material suitable for the site in which it is being placed, be that intraperitoneal or onlay, must be chosen carefully, with sufficient overlap of the mesh with the edge of the fascial deficit and if possible dual methods of fixation. In the case of Mrs S, the only possible improvement that could have been made to reduce the likelihood of recurrence would have been fixation with two methods, such as tacks as well as sutures. Such choices should be thought about on a case-dependent basis in order to further reduce rates of recurrence.

Conflicts of interest

None.

Funding

None.

Consent

The patient has consented to the publication of this case study.

References

1. DDH, Ahm D, We T, Rw K. Open surgical procedures for incisional hernias (Review). 2009;(1).
2. Sanders DL, Kingsnorth AN. The modern management of incisional hernias. *BMJ* [Internet]. 2012;344(May):e2843. Available from: <http://www.ncbi.nlm.nih.gov/pubmed/22573647>
3. Peralta R, Latifi R. Long-term outcomes of abdominal wall reconstruction. what are the real numbers? In: *World Journal of Surgery* [Internet]. 2012 [cited 2019 May 26]. p. 534–8. Available from: <https://link.springer.com/content/pdf/10.1007%2Fs00268-012-1454-y.pdf>
4. Brown CN, Finch JG. Which mesh for hernia repair? *Ann R Coll Surg Engl*. 2010;92(4):272–8.
5. Schmidbauer S, Ladurner R, Hallfeldt KK, Mussack T. Heavy-weight versus low-weight polypropylene meshes for open sublay mesh repair of incisional hernia. *Eur J Med Res* [Internet]. 2005 [cited 2019 May 26];10(6):247–53. Available from: <https://daignet.leiner-wolff.de/site-content/die-daig/fachorgan/archiv/2005/ejomr-2005-vol.10/247%282%29.pdf>
6. Bansal VK, Misra MC, Kumar S, Keerthi Rao Y, Singhal P, Goswami A, et al. A prospective randomized study comparing suture mesh fixation versus tacker mesh

fixation for laparoscopic repair of incisional and ventral hernias. *Surg Endosc Other Interv Tech* [Internet]. 2011 [cited 2019 Jun 17];25(5):1431–8. Available from: <http://sri.sagepub.com/http://online.sagepub.com>

7. Alicuben ET, DeMeester SR. Onlay ventral hernia repairs using porcine non-cross-linked dermal biologic mesh. *Hernia*. 2014;18(5):705–12.
8. CADTH. Biological Mesh: A Review of Clinical Effectiveness, Cost-Effectiveness and Guidelines – An Update [Internet]. 2015;(August).
9. Holihan JL, Nguyen DH, Nguyen MT, Mo J, Kao LS, Liang MK. Mesh Location in Open Ventral Hernia Repair: A Systematic Review and Network Meta-analysis [Internet]. Vol. 40, *World Journal of Surgery*. 2016 [cited 2019 May 26]. p. 89–99. Available from: <https://link.springer.com/content/pdf/10.1007%2Fs00268-015-3252-9.pdf>
10. LeBlanc KA, Whitaker JM, Bellanger DE, Rhynes VK. Laparoscopic incisional and ventral hernioplasty: Lessons learned from 200 patients. *Hernia* [Internet]. 2003 [cited 2019 Jun 18];7(3):118–24. Available from: <https://link.springer.com/content/pdf/10.1007%2Fs10029-003-0117-1.pdf>
11. Klosterhalfen B, Junge K, Klinge U. The lightweight and large porous mesh concept for hernia repair. *Expert Rev Med Devices*. 2005;2(1):103–17.
12. Garcia-Urena Ma, Ruiz VV, Godoy AD, Perea JMB, Gomez LMM, Hernandez FJC, et al. Differences in polypropylene shrinkage depending on mesh position in an experimental study. *Am J Surg* [Internet]. 2007 Apr 1 [cited 2019 May 27];193(4):538–42. Available from: <https://www.sciencedirect.com/science/article/pii/S000296100700044X?via%3Dihub>
13. LeBlanc KA. Laparoscopic incisional and ventral hernia repair: Complications - How to avoid and handle [Internet]. Vol. 8, *Hernia*. 2004 [cited 2019 Jun 18]. p. 323–31. Available from: <https://link.springer.com/content/pdf/10.1007%2Fs10029-004-0250-5.pdf>
14. LeBlanc KA. Laparoscopic incisional hernia repair: Are transfascial sutures necessary? A review of the literature [Internet]. Vol. 21, *Surgical Endoscopy and Other Interventional Techniques*. 2007 [cited 2019 Jun 18]. p. 508–13. Available from: <https://link.springer.com/content/pdf/10.1007%2Fs00464-006-9032-8.pdf>
15. Sauerland S, Walgenbach M, Habermalz B, Cm S, Miserez M, Seiler CM, et al. Laparoscopic versus open surgical techniques for ventral or incisional hernia repair. *Cochrane Database Syst Rev* [Internet]. 2011;(3):CD007781. Available from: <http://www.ncbi.nlm.nih.gov/pubmed/21412910> <http://doi.wiley.com/10.1002/14651858.CD007781.pub2>
16. Liem MSL, GRAAF Y VANDER, VAN STEENSEL CJ, BOELHOUWER RU, CLEVERS GJ, MEIJER WS, et al. Comparison of Conventional Anterior Surgery and Laparoscopic Surgery for Inguinal Hernia Repair. *Surv Anesthesiol* [Internet]. 1997 [cited 2019 Jun 18];41(6):369. Available from: <https://www.nejm.org/doi/pdf/10.1056/NEJM199705293362201?articleTools=true>
17. Yoo A, Corso K, Chung G, Sheng R, Schmitz N-D. The Impact of Surgical Approach on Late Recurrence in Incisional Hernia Repair. *JSL S J Soc Laparoendosc Surg*. 2019;22(4):e2018.00053.
18. Ruiz-Jasbon F, Norrby J, Ivarsson ML, Björck S. Inguinal hernia repair using a synthetic long-term resorbable mesh: results from a 3-year prospective safety and performance study. *Hernia* [Internet]. 2014 [cited 2019 May 27];18(5):723–30. Available from: <https://link.springer.com/content/pdf/10.1007%2Fs10029-014-1249-1.pdf>

19. Oberg S, Andresen K, Rosenberg J. Absorbable Meshes in Inguinal Hernia Surgery: A Systematic Review and Meta-Analysis [Internet]. Vol. 24, Surgical Innovation. 2017 [cited 2019 Jun 17]. p. 289–98. Available from: <https://doi.org/10.1177/1553350617697849>
20. Robinson TN, Clarke JH, Schoen J, Walsh MD. Major mesh-related complications following hernia repair: Events reported to the Food and Drug Administration. *Surg Endosc Other Interv Tech*. 2005;19(12):1556–60.
21. Sun P, Cheng X, Deng S, Hu Q, Sun Y, Zheng Q. Mesh fixation with glue versus suture for chronic pain and recurrence in Lichtenstein inguinal hernioplasty (Review). *Cochrane Database Syst Rev* [Internet]. 2017;(2). Available from: <http://onlinelibrary.wiley.com/doi/10.1002/14651858.CD010814.pub2/full>
22. Sanchez VM, Abi-Haidar YE, Itani KMF. Mesh Infection in Ventral Incisional Hernia Repair: Incidence, Contributing Factors, and Treatment. *Surg Infect (Larchmt)*. 2011;12(3):205–10.
23. Abramov D, Jeroukhimov I, Yinnon AM, Abramov Y, Avissar E, Jerasy Z, et al. Antibiotic prophylaxis in umbilical and incisional hernia repair: a prospective randomised study. *Eur J Surg* [Internet]. 1996 [cited 2019 May 27];162(12):945--8; discussion 949. Available from: <https://www.researchgate.net/publication/14206292>
24. Sanchez-Manuel F, Seco-Gil J. Antibiotic prophylaxis for hernia repair. *Cochrane Database Syst Rev*. 2004;(2).
25. Choi JJ, Palaniappa NC, Dallas KB, Rudich TB, Colon MJ, Divino CM. Use of mesh during ventral hernia repair in clean-contaminated and contaminated cases: Outcomes of 33,832 cases. *Ann Surg*. 2012;255(1):176–80.
26. Cavallaro A, Menzo E Lo, di Vita M, Zanghi A, Cavallaro V, Veroux PF, et al. Use of biological meshes for abdominal wall reconstruction in highly contaminated fields. *World J Gastroenterol*. 2010;16(15):1928–33.
27. Bittner R, Bingener-Casey J, Dietz U, Fabian M, Ferzli GS, Fortelny RH, et al. Guidelines for laparoscopic treatment of ventral and incisional abdominal wall hernias (International Endohernia Society (IEHS) - Part 1. *Surg Endosc*. 2014;28(1):2–29.